



PATIENT

Augie Mitchell

PRESENTING CLINICAL SIGNS

Presentd for loss of energy noted systolic murmur grade 3/6, louder on left. Meds: Librela, galliprant, TCVM Hindquarter Weakness, tramadol

SPECIES

Canine

Abnormal PE/Chem/CBC/UA Results: CBC - WNL Chem - Low TP (4.6) , elevated ALT (227) & Alk Phos (522) SDMA - 8 T4 - 2

ULTRASONOGRAPHIC EXAMINATION OF THE ABDOMEN AND HEART

BREED

Havanese

SEX

MN

AGE

12yr

WEIGHT

22.9lb

| CANINE CARDIAC PARAMETERS | MR VMAX (m/s) | TR VMAX (m/s) | LA/AO M-mode | LA/AO (Heart Base; Swe) | FS (%) | EF (%) | EPSS (cm) |
|---------------------------|---------------|---------------|--------------|-------------------------|----------------------|--|--|
| NORMAL PARAMETER | 4.5-5.5 | <2.7 | 1.3 | Up to 1.6 | 28-40 | 40-100 | <0.6 |
| PATIENT | 5.2 | 3.4 | -- | 2.4 | 52 | 84 | 0.25 |
| CANINE CARDIAC PARAMETERS | HR (BPM) | AV VMAX (m/s) | PV MAX (m/s) | BODY WEIGHT (kg) | LAD LA MAX 4 Chamber | LVIDd Avg; 2D and m-mode short axis (cm) | LVIDs Avg; 2D and m-mode short axis (cm) |
| NORMAL PARAMETER | 50-100 | 0.7-1.7 | 0.7-1.6 | | | | |
| PATIENT | -- | 1.3 | 0.8 | -- | 4.4 | 3.7 | -- |

INTERPRETED BY

R. McKenzie Daniel, DVM, DABVP (Canine and Feline)

Cardiac Presentation

The echocardiogram in this patient demonstrated severely increased left atrial size. The cranial and caudal mitral valve leaflets presented thickening consistent with endocardiosis with valvular prolapse Doppler indicated severe measurable insufficiency. The left ventricle presented thicknesses with alinear contour and significant increased LV dimension and sphericity. The myocardium presented normal echogenicity without subjective evidence of significant fibrotic or ischemic disease.

IMAGING PERFORMED BY

Rebecca Hamilton

Contractility of the ventricular walls was adequate and in normal range for this patient evidenced by the fractional shortening measurement and subjective evaluation of the different regions of the myocardium. The left ventricular outflow tract demonstrated normal laminar flow and subjective structural integrity. Mild aortic valve insufficiency on Doppler. The right atrium and auricle revealed mildly enlarged size with normal structure and content. No evidence of masses was noted. Tricuspid valvular assessment demonstrated thickening with significant GTR on Doppler. The right ventricle was mild increased size compared to the LV with normal chordae structure, myocardial echogenicity and thickness. Pulmonic tract assessment revealed normal valve structure, laminar flow, and diameter (approx.1:1 pa/ao ratio). No visible pericardial or free pleura fluid was noted. No echographically detectable evidence of cardiac / pericardial tumors was visible. Subjective tachycardia present.

HOSPITAL NAME

The Veterinary Hospital

REFERRING VET

Dr Johnson

Urinary System

The urinary bladder, trigone, cystourethral junction, and visible pelvic urethra exhibited normal thickness and tone. Anechoic urine was present in the lumen with no evidence of urine/lumen

INVOICE
23495

DATE
01/08/2026



| | |
|--|---|
| PATIENT | sediment, mineral, or calculi. The ureteral papillae were normal. The ureters were not visible which is normal. No evidence of inflammatory or neoplastic changes was noted. |
| Augie Mitchell | |
| SPECIES | Normal size and margination were present in the kidneys. A normal 1:3 cortex / medulla ratio was maintained. The medulla and cortices were uniform in texture with some increased echogenicity and mild to moderate loss of corticomedullary symmetry and definition expected for the age of the patient. No evidence of pelvic dilation was present. Non-obstructive medullary renoliths were present with left kidney cortical cysts. The left kidney measured 4.6 cm in length. The right kidney measured 5.0 cm in length. |
| Canine | |
| BREED | The area of the aortic trifurcation was free of pathology. |
| Havanese | |
| | Adrenal Glands |
| SEX | Bilateral symmetrical adrenal gland enlargement with uniformly hypoechoic parenchyma was present. The left adrenal gland measured 0.65 cm width at the caudal pole. The right adrenal gland measured 0.77 cm width at the caudal pole. |
| MN | |
| | Spleen |
| AGE | Generalized splenomegaly with prominent congested vasculature. Mildly expansive homogenous hypoechoic nodules were present, an example in the medial spleen measured 2.6 cm in diameter with mild associated symmetrical capsule distortion. |
| 12yr | |
| WEIGHT | Liver/Gallbladder |
| 22.9lb | The liver presented enlarged in size with symmetrical yet swollen contour. The parenchyma exhibited conserved uniform parenchyma with normal echogenicity isoechoic to the spleen and falciform fat. The hepatic vasculature was dilated in appearance, most notable at the level of the hepatic vein / caudal vena cava junction, without evidence of thrombosis. The gallbladder was non-distended in size with thin walls and mild non-organized debris. No evidence of gallbladder/peripheral gallbladder inflammation or wall edema was present. The cystic and common bile ducts were normal. |
| INTERPRETED BY | Gastrointestinal |
| R. McKenzie Daniel, DVM, DABVP (Canine and Feline) | The stomach presented intact wall layering with a normal wall layer ratio. The lumen of the stomach was empty with no signs of ileus, obstruction or foreign material. |
| | The intestinal walls demonstrated intact wall layering and maintained 1:3 muscularis / mucosa ratio. The mucosa exhibited mild decreased echogenicity with occasional mucosal speckling. A segmental to diffuse ileus pattern consisting of mild fluid accumulation in the intestinal lumen was present without obstruction or foreign material. |
| IMAGING PERFORMED BY | Normal visible colon wall layers were present with apparent formed feces in lumen. |
| Rebecca Hamilton | |
| HOSPITAL NAME | Pancreas |
| The Veterinary Hospital | The parenchyma of the left limb, body and right limb of the pancreas presented isoechoic to the adjacent omental fat. A normal curvilinear capsule contour of the pancreas was present. The visible pancreatic duct was normal. No signs of active inflammation or neoplastic disease was evident. |
| REFERRING VET | Free Abdomen |
| Dr Johnson | Moderate to significant volume ascites and generalized homogenous hyperechoic omentum was present. |
| INVOICE | |
| 23495 | |
| DATE | |
| 01/08/2026 | |



PATIENT

No visualized significant omental lymphadenopathy.

Augie Mitchell

ULTRASONOGRAPHIC FINDINGS

Primary

SPECIES

Canine

- Chronic mitral valve disease, left heart volume overload (stage C)
- Pulmonary hypertension
- Aortic valve insufficiency
- Subjective tachycardia
- Congestive hepatomegaly
- Mild gallbladder debris
- Splenomegaly with mild expansive splenic nodules and evidence of congestion
- Segmental non-obstructive intestinal ileus
- Moderate to significant volume ascites and omental hyperechogenicity
- Chronic renal changes with medullary renoliths
- Non-specific bilateral mild adrenomegaly

BREED

Havanese

SEX

MN

AGE

12yr

INTERPRETATION OF THE FINDINGS & FURTHER RECOMMENDATIONS

Severe chronic valvular disease has progressed to left heart volume overload, consistent with congestive left-sided heart failure. Concurrent pulmonary hypertension and tachycardia predisposes to right-sided heart failure as evidenced by hepatic congestion and cranial abdomen ascites. Potential for concurrent tachyarrhythmia, i.e. atrial fibrillation, is indicated. Cardiac prognosis is likely poor as this patient will remain at increased risk for recurrent congestive heart failure, progressive pulmonary hypertension, malignant arrhythmia, and potential sudden death.

WEIGHT

22.9lb

INTERPRETED BY

R. McKenzie Daniel,
DVM, DABVP
(Canine and Feline)

Hospitalization with IV diuretic / rate control therapy until stabilization is recommended. Pimobendan 0.3 mg/kg BID, Lasix/ spironolactone combination, 1-2 mg/kg PO BID, ACE inhibitor 0.5 mg/kg BID if evidence of systemic hypertension with monitoring of systemic BP, HR, and renal parameters recommended. Echocardiographic monitoring is indicated if patient is stable.

IMAGING PERFORMED BY

Rebecca Hamilton

The splenic nodules may indicate hyperplasia, hematopoiesis or myelolipomas, although potential for concurrent splenic neoplasia is not excluded.

HOSPITAL NAME

The Veterinary
Hospital

REFERRING VET

Dr Johnson

INVOICE

23495

DATE

01/08/2026



PATIENT

Augie Mitchell

SPECIES

Canine

BREED

Havanese

SEX

MN

AGE

12yr

WEIGHT

22.9lb

INTERPRETED BY

R. McKenzie Daniel,
 DVM, DABVP
 (Canine and Feline)

IMAGING PERFORMED BY

Rebecca Hamilton

HOSPITAL NAME

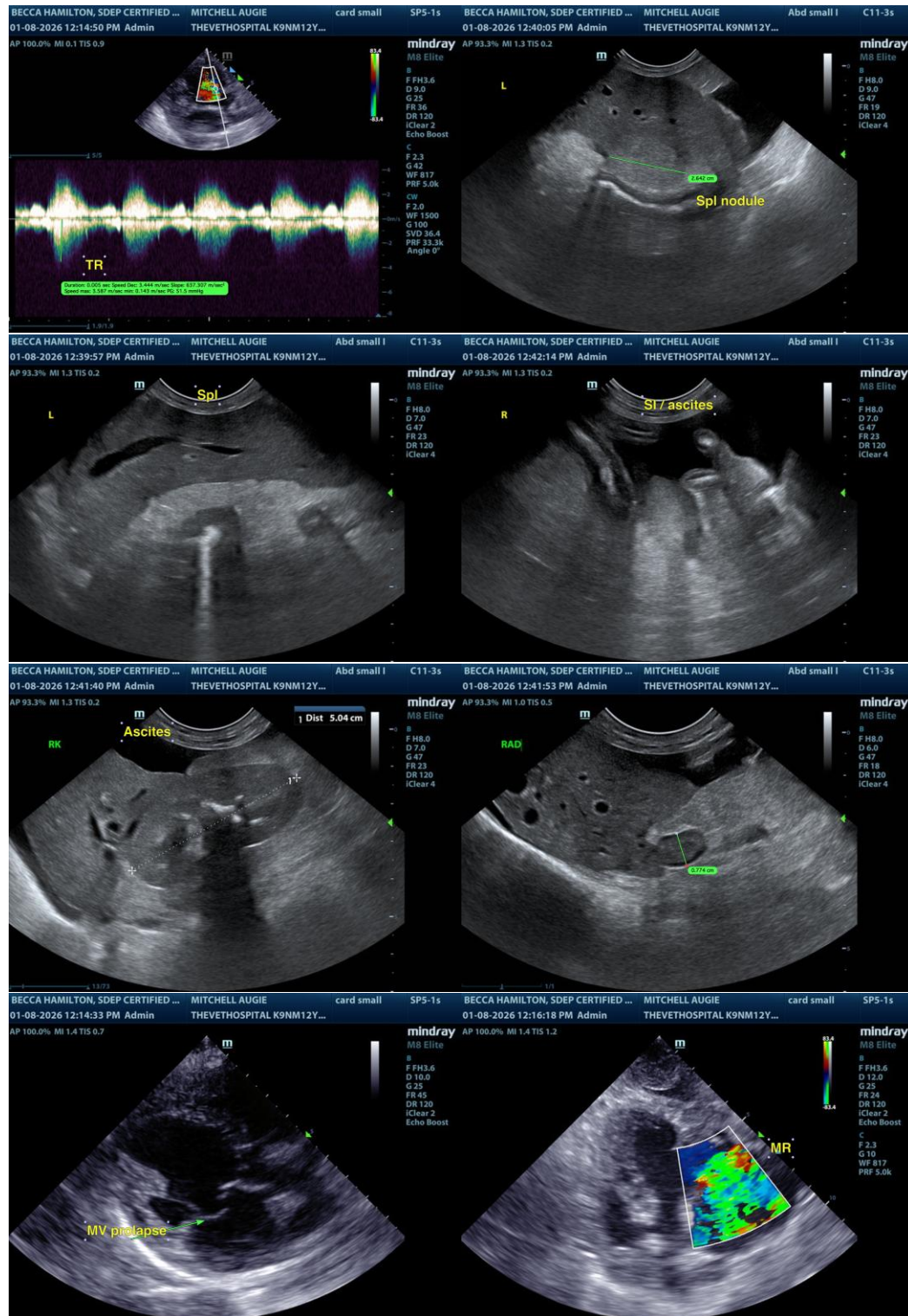
The Veterinary
 Hospital

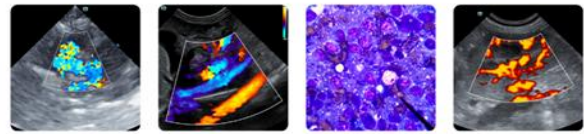
REFERRING VET

Dr Johnson

INVOICE
 23495

DATE
 01/08/2026





PATIENT

Augie Mitchell

SPECIES

Canine

BREED

Havanese

SEX

MN

AGE

12yr

WEIGHT

22.9lb

INTERPRETED BY

R. McKenzie Daniel,
 DVM, DABVP
 (Canine and Feline)

IMAGING PERFORMED BY

Rebecca Hamilton

HOSPITAL NAME

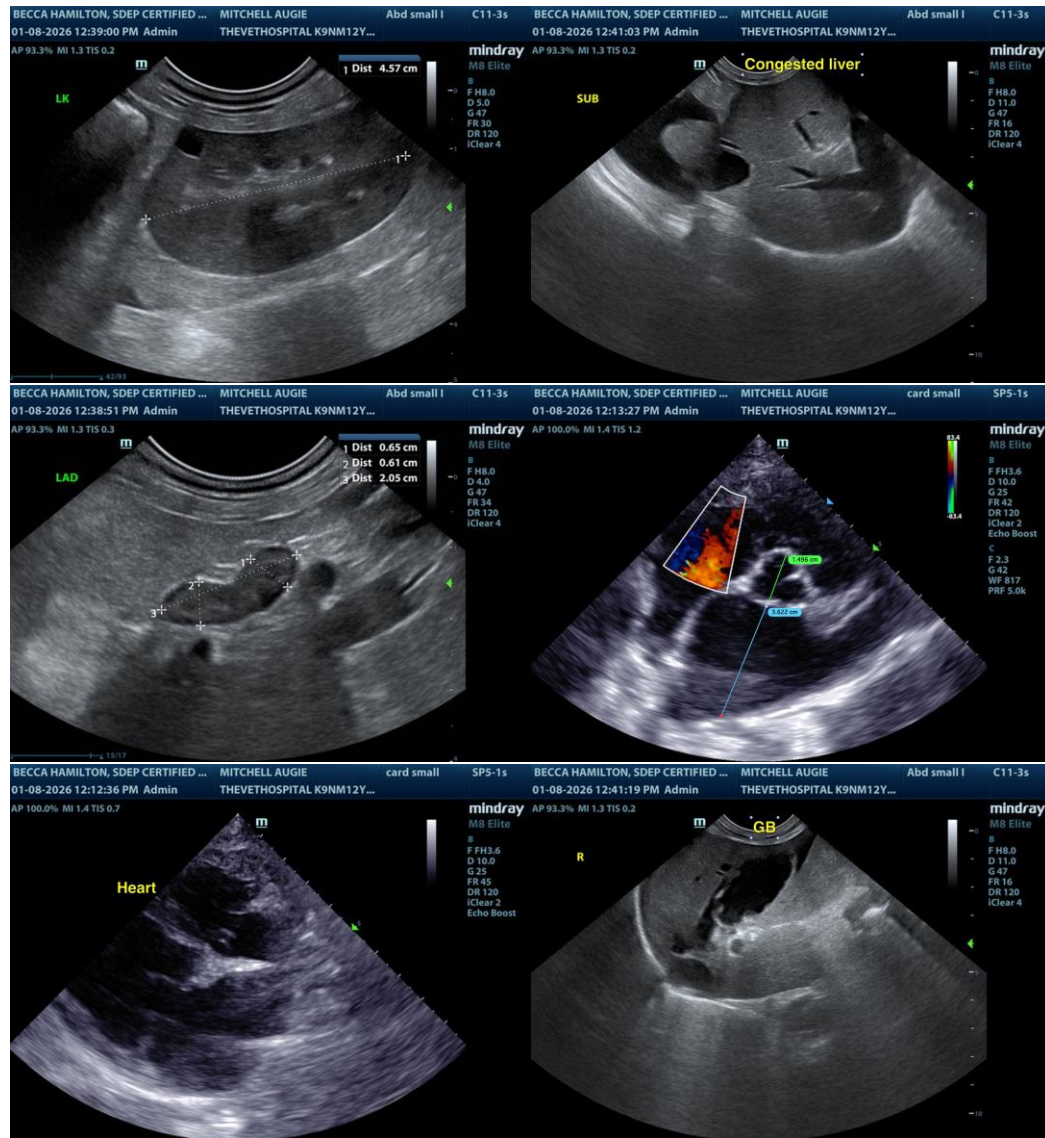
The Veterinary
 Hospital

REFERRING VET

Dr Johnson

INVOICE
 23495

DATE
 01/08/2026



The information and recommendations provided are based on the images presented by the referring veterinarian/sonographer. No evaluation can be communicated regarding pathology that was not visible in the image/video clips provided.

Thank you for this referral. If the clinical or image interpretation does not parallel your findings or if I can be of any further assistance, please contact me.

R. McKenzie Daniel, DVM, DABVP (Canine/Feline Practice)
info@sonopath.com